

SUBCUTANEOUS NODULES IN ACUTE RHEUMATIC FEVER – A CASE REPORT

J Dinesh Kumar^a, S Saji James^a, P Venkataraman^a, P SubbaRao^a, M S Latha^a

ABSTRACT:

Acute Rheumatic fever commonly presents with features of arthritis, carditis and less commonly with chorea and erythema marginatum. The association of subcutaneous nodules in rheumatic fever with carditis is <1%. We

present a case study of this rare presentation with review of literature.

Key Words: Acute Rheumatic fever, Subcutaneous nodules, Rheumatic heart disease, Carditis.

SRJM 2011;4:40-41

INTRODUCTION:

The prevalence of acute rheumatic fever and rheumatic heart disease in Indian population varies from 0.5/1000 to 11/1000 as documented in various studies.^[1] Acute rheumatic fever is a non – suppurative complication of group A beta hemolytic streptococcal sore throat. Rheumatic fever usually affects joints, skin, subcutaneous tissues, brain and heart.^[2] Except heart, all other effects are reversible, needing only symptomatic relief during the episodes. Significant cardiac complications like valvular heart disease can occur if secondary prophylaxis were not followed.^[3]

CASE REPORT :

A 10 year old boy, apparently normal till 1½ months back, first had fever and throat pain lasting for 3-5 days, treated symptomatically. One month later he complained of pain in both knee joints, associated with swelling and redness of the joints, restricting his daily activities, which subsided by 1 week. After a week, he developed fever, pain in both ankle joints, chest pain and nodular lesions over both extensor aspect of elbows.

On examination, 3 to 4 subcutaneous nodules could be seen on the extensor aspect of both elbows which were rounded, firm, mobile and non tender each measuring 0.5 to 1 cm in size. He also had hyperdynamic precordium, pericardial rub, apical impulse at 6th intercostal space half an inch lateral to mid clavicular line, grade 3/6 pansystolic murmur radiating to axilla and back and loud P2.

Blood investigations revealed ESR of 57mm/hr and raised C- Reactive Protein, Hb 7.3gm/dl, Anti Streptolysin O – 200 IU/L, throat culture positive for streptococcal pyogenes. Echo done revealed severe mitral regurgitation, dilated Left atrium and Left ventricle, thickened mitral valve and minimal pericardial effusion and pulmonary hypertension of 46 mm Hg. Clinical examination of the patient ruled out any other systemic involvement apart from cardiovascular system.

CORRESPONDING AUTHOR :

Dr. SAJI JAMES

Associate Professor

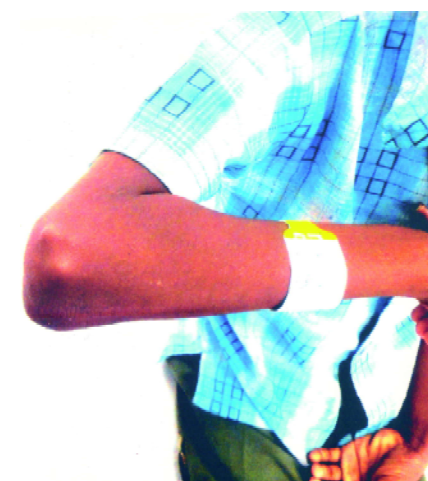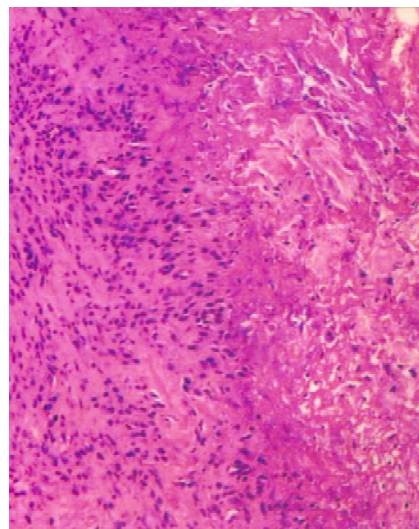
Department of Paediatrics, SRMC & RI

Sri Ramachandra University,

Porur, Chennai 600116, Tamil Nadu, India.

Email id: dr.sajijames@gmail.com

^aDepartment of Paediatrics, SRMC & RI



Excision biopsy of the subcutaneous nodule was done to confirm the diagnosis which showed fibrocollagenous tissue with interstitial spindle cells, collagen denegration and associated histiocytic reaction with occasional neutrophil, features suggestive of rheumatic nodules.

He was treated with a stat dose of 0.6 million units of Benzathinepenicillin and Steroid 2mg/kg/day which was tapered at a dose of 2.5 mg every 3rd day after 2 weeks, Aspirin was started at a dose of 75 mg/kg during the tapering of steroids, and given for a total period of 10 weeks. He was started on low dose diuretics for 2 weeks and stopped. After two weeks all nodules were slowly disappeared.

DISCUSSION:

According to modified Jones criteria, the diagnosis of Acute Rheumatic Fever (ARF) can be made if it fulfills with 2 major criteria or 1 major and 2 minor criteria with supporting evidence of antecedent streptococcal infection. The major criteria are poly arthritis, carditis, rheumatic chorea, erythema marginatum and subcutaneous nodules. Minor criteria includes fever, arthralgia, raised acute phase reactant (erythrocyte sedimentation rate, C-reactive protein, prolonged PR interval). Supporting evidence of antecedent group A streptococcal infection like positive throat culture or rapid streptococcal antigen, elevated or rising titer of Antistreptolysin O.^[4] Subcutaneous nodule (SCN) is one of the major clinical criteria to diagnose Acute Rheumatic fever (ARF). Subcutaneous nodules have been reported in < 1% to 21 % of cases.^[5] Subcutaneous nodules were invariably associated with severe carditis. They usually appear several weeks after the onset of the acute episode, persist from days to weeks and rarely last longer than one month. The nodules are small, varying in size from millimeters to 2 centimeters, firm, painless and fully movable under the skin. They are encountered in clusters, on the extensor surface of the joints and overlying bone prominences, mainly in large joints of limbs, knuckles, scalp and along the spine in the paravertebral areas.

A prospective study of 42 cases of ARF with SCN attempts to analyse the accuracy of such statements.^[6] The group comprised of 12.5% of 336 consecutive cases of ARF. Other major criteria associated with SCN were carditis in 38 (90.4%), arthritis in 33 (78.5%) and chorea in two (4.7%). No evidence of carditis could be found in 4 (9.5%). When a detailed study of SCN was done the average number of nodules found in the group was 18 (range 4-49). Thirteen (30.9%) had less than 10 nodules and 5 (11.9%) had only 4-5 nodules. With initiation of treatment SCN disappeared within 4 weeks in 29 (69%), within next 5-8 weeks in 8 (19%) and within 9-12 weeks in 3 (7.1%). In two cases (4.7%) multiple nodules were observed 12 weeks later when all other evidences of activity had disappeared. Number of nodules appearing in ARF might be quite small and they could persist for long inspite of treatment.^[7] Subcutaneous nodules never present as a sole manifestation of Rheumatic fever and Subcutaneous nodules are not exclusive to Rheumatic fever. They occur in 10% of children with Rheumatoid arthritis.^[8]

The most common differential diagnosis is the rheumatoid nodule. Nodules in acute rheumatic fever are smaller and more short lived than the nodules of the Rheumatoid arthritis. Although elbows are most frequently involved in both diseases, Rheumatic fever nodules are more common on olecranon while Rheumatoid nodules are usually found 3-4 cms distally.^[9] The other differential diagnosis are Lipoma, Sebaceous cyst, Xanthomas, Erythema Nodosum, Polyarteritis nodosa.

There is no specific treatment for subcutaneous nodules and it will disappear when the carditis is adequately treated. Prognosis mainly depends upon the presence or absence of carditis at the initial attack of Rheumatic fever.

REFERENCES

1. Savitri S: Rheumatic Heart Disease: is it declining in india? *Indian Heart J* 2007; 59: 9 -10.
2. English PC. Rheumatic fever in America and Britain. A biological, epidemiological and medical history. New jersey: Rutgers university press; 1999; 17-52
3. Sanyal SK, Berry AM, Duggal S, Hooja V, Ghosh S. Sequelae of the initial attack of acute rheumatic fever in children from north india. A prospective 5-year follow – up study. *Circulation* 1982; 65: 375 –79.
4. Special writing group of the committee on Rheumatic fever, endocarditis and Kawasaki disease of the council on cardiovascular disease in the young of the American Heart Association: guidelines for the diagnosis of Rheumatic fever, Jones criteria 1992 update. *JAMA* 1992; 268: 2069 –73.
5. Anil Kumar Singhi, Prashant Bobhate, Mahesh Kappanayil. Acute Rheumatic Fever, Subcutaneous Nodules and Carditis. *Circulation*. 2010; 121: 946-7.
6. Robert H. Anderson , Edward S. Baker, Daniel J , Andrew N. Michael, Gil Warnosky: *Textbook of Paediatric cardiology*, 3rd edition, Churchill livingstone Elsevier publication, 2011; 1103.
7. Subcutaneous nodules in acute rheumatic fever – an analysis of age old dictums, *Indian Heart J* 1993; 45: 463-7.
8. Myung K Park: *Textbook of Paediatric Cardiology*, 5th edition, Elsevier Mosby; 383 –5
9. Marc C. Hoshberg, Alan J. Silman, Josef S. Smolan, Michael Weinblatt, Michael H. Weisnar: *Textbook of Rheumatology*, 5th edition, Elsevier Mosby, 2011; 829-30.