

PRIMARY TUBERCULAR MASTOIDITIS – A RARE PRESENTATION

A. Ravi kumar ^a, Senthil .K ^a, Prasanna Kumar. S ^a, Gopinath ^a, Gaurav Bambha ^a

ABSTRACT:

Tuberculosis can masquerade any disease; primary tubercular mastoiditis is a rare clinical entity. We report a case of tubercular mastoiditis which presented as a postaural swelling with intact tympanic membrane, no hearing loss. The surgical findings revealed mastoid and

extradural extension of disease. Histopathological examination of excised tissue clinched the diagnosis. There was no evidence of pulmonary or any other tubercular foci.

Key words: Primary tubercular mastoiditis, Silent mastoiditis.

INTRODUCTION:

Tubercular mastoiditis was first described by Jean Louis Petit in the 18th century; Wilde in 1853 discussed the classical picture of tuberculosis otitis media as a disease characterised by painless, insidious onset of ear discharge, multiple perforations in the tympanic membrane, pale granulations in middle ear cleft. Politzer discussed the destructive nature of this disease in 1882; it was in 1892 that Koch demonstrated the tubercle bacilli.[1] The incidence of tuberculosis otitis media has been reported to be 0.04% to 0.9% of all Chronic suppurative otitis media (CSOM) in the developed countries. [3,4] Tuberculosis affects the middle ear through three routes either through the Eustachian tube, blood borne dissemination or direct implantation through the external auditory canal and tympanic membrane perforation. The incidence is thought to be more and is on the rise in the developing countries[10], In recent years extra pulmonary tuberculosis has more frequently been associated with mastoiditis in patients with immunodeficiency state.

Primary tubercular mastoiditis is a silent tubercular mastoiditis i.e. there is no history of ear discharge, normal tympanic membrane and hearing and no evidence of tubercular foci in the lungs or any where else in the body.[2] Silent mastoiditis refers to clinically undetected or undetectable middle ear pathology.

CASE REPORT:

A 12yr, male child presented to our OPD with left postaural swelling for the past 2 months, which was insidious in onset progressive and painless. There was no history of ear discharge, trauma, ear surgery in the past. There was no history of fever. However patient complained of dull global headache.

Examination showed a smooth 2x4 cm left postaural swelling, the skin over the swelling was normal (Fig.1), no

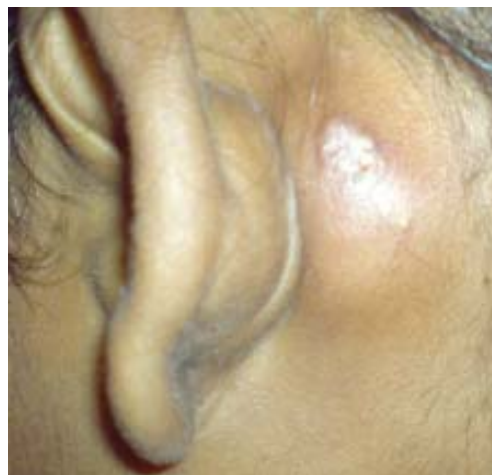

Fig. 1 Post Auricular Swelling on the left side

local rise in temperature, nontender, soft in consistency, with no fluctuation, and not reducible. The postaural sulcus was normal. Otoscopy showed a normal mobile tympanic membrane. Tuning fork tests showed normal response. Pure tone audiogram showed normal hearing. A provisional diagnosis of chronic postaural lymphadenitis was made. Routine blood test were normal except ESR which was 12mm in 1st hr. Chest X-ray was normal, Mantoux test was negative FNAC was suggestive of reactive lymphadenitis. Incisional biopsy was done under local anaesthesia. During the procedure pale granulation was noted, which was extending into the mastoid cortex; Histopathological examination (HPE) showed features of chronic granulomatous disease suggestive of tubercular or fungal granuloma.

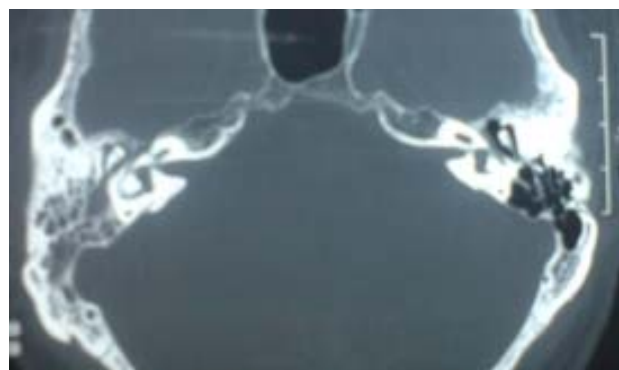


Fig.2. HRCT temporal bone suggestive of left mastoiditis

CORRESPONDING AUTHOR:

Prof. A Ravi Kumar

Head of Dept, E.N.T. Head & Neck Surgery
SRMC & RI, Sri Ramachandra University
Porur, Chennai – 600 116

email: entsrhc@yahoo.co.in.

^aDepartment E.N.T. Head & Neck Surgery

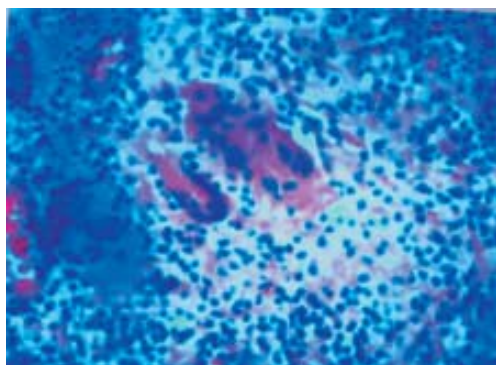


Fig .3. Microscopic view of mastoid granulation tissue showing giant cell in an ill defined epithelioid granuloma (Hematoxylin and eosin stain x 200)

In consultation with pulmonologist antitubercular therapy was started (ATT) (2HRZE/ 4HR) based on the histopathological report and clinical suspicion and was discharged. 2 weeks later the patient came back with a discharging sinus in the post aurial region and persistent global head ache. HRCT scan of the temporal bone and brain showed soft tissue opacity in the mastoid suggestive of mastoiditis. (Fig.2). A differential diagnosis of congenital cholesteatoma, tuberculosis otitis media (TOM), or fungal granuloma was considered. He was taken up for surgery. Through a postaural incision the fistula and granulations were excised. The mastoid cortex was found to be filled with pale granulations which were extending up to the tip cells below. The sinus plate was found to be eroded and granulations were found on the sinus and the dura. Granulations were carefully removed. The mastoid antrum was found to be free of disease, tympanum was normal with normal ossicular chain. Granulation tissue was sent for histopathological examination (HPE), acid fast bacilli (AFB) staining and culture. AFB staining and culture were negative, HPE showed chronic inflammatory granulation tissue with ill defined epithelioid granulomas having multinucleated giant cells and caseating necrosis suggestive of tuberculous granuloma [fig. 3]. He was continued on ATT and after follow up of 6 months he is asymptomatic with normal hearing (fig. 4).

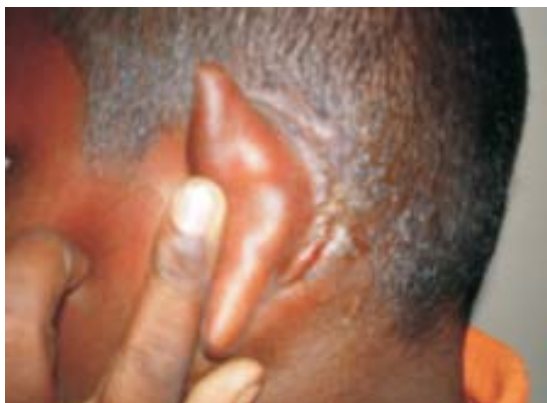

Fig.4. Post aurial wound after 6 months after surgery

DISCUSSION:

The classical description of tubercular otitis media is a painless, odourless otorrhea, insidious in onset with multiple perforation of the tympanic membrane, with abundant granulation and hearing loss which is out of proportion to the clinical finding. Contrary to the classical description, in our case there was no evidence of middle ear involvement with an intact ossicular chain and no hearing loss.

The most common mode of infection is secondary to spread of infection from the lungs; the route of infection is thought to be via the Eustachian tube, haematogenous route or via the perforated tympanic membrane. Kim et al[8] have reported a case in which Tympanostomy tube insertion was thought to be the cause of tubercular otitis media; A review of literature in showed very few cases in which there was no involvement of the tympanum. Similarly there was no involvement of the tympanum in the case we report here and the disease was only confined to the mastoid. In our case there was no evidence of pulmonary tuberculosis and since the tympanum was free of any disease, the route of transmission could not have been through the Eustachian tube, and could have been only by haematogenous route.

The diagnosis of tubercular otitis media requires a high index of suspicion even in the absence of pulmonary Koch's, demonstration of AFB in the ear discharge is difficult. The positivity for AFB in ear discharge varies from 5 to 35% and on repeated examinations it improves to 50% [7], diagnosis of extra pulmonary tuberculosis is essentially clinical, [10] and antitubercular therapy can be started only on clinical or histopathological suspicion.[9] Early institution of ATT is mandatory and is the main stay of treatment especially to avoid serious complication. The role of surgery is limited and indications for surgical intervention include cases unresponsive to medical therapy, extensive disease with bone sequestrae.

Untreated TOM can result in permanent, severe sequel, such as facial paralysis, hearing impairment, and intracranial dissemination of infection. Therefore, early suspicion and timely diagnosis are of paramount importance.

CONCLUSION:

Primary tubercular mastoiditis is a rare clinical entity, the diagnosis of which requires a high index of suspicion. Early institution of treatment results in resolution of disease and prevention of serious complications [5]. In this case we have reported a rare presentation of tubercular mastoiditis without middle ear involvement. This case where disease extended to dura shows that silent mastoiditis can be a potential cause of complication such as meningitis inspite of presence of intact tympanic membrane.

REFERENCES:

1. Awam MS, Salahudin I. Tuberculous otitis media two case reports and literature review. *Ear nose throat J.* 2002;81:792-4
2. Paparella MM, Kimberley BP, Alleva M, the concept of silent mastoiditis its importance and complications. *Otolaryngol Clin North Am* 1991; 24:763-74.
3. Siqueira BR, Palheta Neto FX, Gomes AP, Pezzin-palheta AC. Tuberculosis related middle ear otitis; a rare occurrence. *Revista da Sociedade Brasileira de Medicina Tropical.* 2002;35:267-8.
4. Grewal DS, Baser B, Shahani RN, Khanna S. Tuberculous otitis media presenting as complications; report of 18 cases. *Auris Nasus Larynx* 1991;18 :199-208.
5. Djerić DR, Schachern PA, Paparella MM, Jaramillo M, Haruna S, Bassioni M. Otitis media (silent): A potential cause of childhood meningitis. *Laryngoscope* 1994;104:1453-60.
6. Karkera GV, Shah DD. Silent mastoiditis-tuberculous aetiology presenting as facial nerve palsy. *Indian J Otolaryngol Head Neck Surg* [serial online] 2006 [cited 2007 Jun 12]; 58:108-110.
7. Manju Mahajan, D.S. Agarwal, N.P. Singh and D.J. Gadre, tuberculosis of the middle ear - a case report, *Ind. J. Tub.*, 1995, 42, 55
8. Kim, Chang; Jin, Jae; Rho, Young-Soo, Tuberculous otitis media developing as a complication of tympanostomy tube insertion *European Archives of Oto-Rhino-Laryngology*, Volume 264, Number 3, March 2007, pp. 227-230(4)
9. James R. Vevaina, Roger C. Bone, E. (Edwin) Kassoff, *Legal Aspects of Medicine*: page 268.
10. Editorial Extra-Pulmonary Tuberculosis : Coming out of the Shadows , *Indian J Tuberc* 2004; 51:189-190