

A RARE TYPE OF RIGHT SIDE BOCHDALEKS DIAPHRAGMATIC HERNIA PRESENTING IN AN ADULT : CASE REPORT

M Subramanian*, Prasad A Sasnur

ABSTRACT

Literature describes less than a dozen cases of right-sided diaphragmatic hernia. Here we present an unusual case of this kind in an adult patient. The hernial contents were the Liver, stomach, large bowel. Diaphragmatic hernias, in which peritoneal contents are

found in the thoracic cavity, are well documented in medical literature. Hernias of this type may be congenital in origin, such as Morgagni's or Bochdalek's hernia, or traumatic in origin.

Key words : Diaphragmatic hernia, Right diaphragmatic hernia, adult diaphragmatic hernia, case report

INTRODUCTION

This case is reported for its rarity because it is seen in an elderly patient on the right side of the diaphragm with liver being one of the contents of hernia.

CASE REPORT

A 55-year-old male patient presented with dyspnoea, vomiting and abdominal pain since one month. CT Scan revealed herniation of right diaphragm, raised liver in to the right lower thorax along with hepatic flexure [Fig1]. Dilated stomach and duodenum with herniation of the hepatic flexure were seen on Barium meal study [Fig2]. Lung functions were normal.

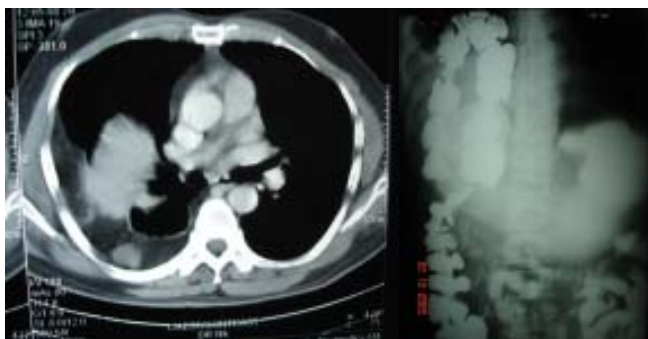


Fig. 1 & Fig 2.

Operative findings— Diaphragm was thinned out and distal stomach, duodenum, omentum, right lobe of the liver, hepatic flexure herniated into the right side of chest through large space of Bochdalek was observed on thoracoabdominal incision[Fig3]. Diaphragm was repaired through abdomen using prolene interrupted sutures and Marlex mesh reinforcement. Postoperative period was uneventful and he is doing well after nine months of surgery.

CORRESPONDING ADDRESS

*Dr. M. SUBRAMANIAN

Head of the Department
Department of Surgical Gastroenterology
SRMC & RI (DU)
email: gastrosurg@yahoo.co.in

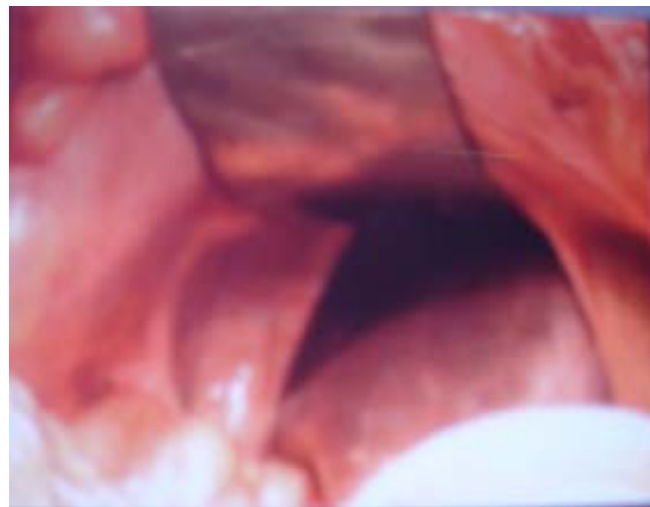


Fig. 3

DISCUSSION

The true incidence of Congenital diaphragmatic hernia is 1 in 7000 live births[1] while right side diaphragmatic hernia (15%) is rare comparing to left side diaphragmatic hernia (85%) [2] because liver plugs the opening. Congenital diaphragmatic hernia usually develop in the small areas of weakness in the diaphragm (space of Bochdalek and Morgagni) observed during fetal development where diaphragm has to sustain pressure developed by growing lungs above and intestines returning in to the abdomen below. These canals get normally closed by the pleuroperitoneal membranes at 8th week of gestation. Failure to close due to various reasons leads to Bochdalek hernia [3]. Neonates are born with respiratory distress, tachypnea, cyanosis. Infants with well developed lungs with no symptoms immediately (24hrs) after birth will do well after surgery[4]. In adults, chest or abdominal pain (75%), dyspnea (75%), and vomiting (25%) are common symptoms, whereas bowel obstruction and strangulation are not[5]. Diaphragmatic hernia rarely presents during adult life and patient do well after surgery [6].

REFERENCES :

- 1) Bochdalek's hernia in an adult with colon necrosis-*Hernia* 2005,9(3); 284-7
- 2) Case report – Right sided diaphragmatic hernia in an adult without history of trauma: *European Journal of General Medicine* 1(3):pp. 55-57
- 3) Congenital diaphragmatic hernia in a patient with tetrasomy 9p – *J Pediatr surg* 2005, 40:29-31.
- 4) *Mastery of surgery* : Nyhus and Baker, 4th edition,
- 5) Meng RL, Straus A, Milloy A, et al. Intrapericardial diaphragmatic hernia in adults. *Ann Surg* 1979, 189: 359-66
- 6) Congenital Bochdalek diaphragmatic hernia in an adult-*J Assoc Physicians India* 1987, 35:662-4



Thank You Dear Audiologist

Thanks for detecting my hearing loss when I was still a baby.


Thanks for fitting hearing aids on both my little ears which opened up the world of sound to me.
Thanks for referring me for a cochlear implant when I could not hear all the sounds with my hearing aids.

I can now hear all those sounds and even a whisper with my cochlear implant. I have learnt to speak and can now express my gratitude to you in spoken words - Thank You.

Smriti and Muskan above are 2 of the over 800* individuals in India who have benefited from Cochlear's Nucleus Cochlear Implant Systems.
Nucleus Cochlear Implant Systems are a proven reliable option for children with bilateral severe to profound sensorineural hearing loss, who are as young as one year of age.
Over 20 leading institutions in the government and private sector in India have adopted Cochlear's Nucleus Cochlear Implant technology and 20* families opt for Nucleus Cochlear Implant Systems every month due to the reliability and good outcomes. (* As on December 2005)

For more information, visit www.cochlear.com or contact:

PIKA MEDICAL (P) LTD
1212 Mittal Tower B, 6 MG Road, Bangalore 560001.
Tel; 080 25594757 Fax: 080 25598254 email: pika@pobox.com



Hear now. And always **Cochlear**