

## ORBITAL APEX SYNDROME IN A CHILD

A. Ravikumar<sup>\*a</sup>, K. Senthil<sup>a</sup>, Padma Srikanth<sup>b</sup>, Vivek Sasindran<sup>a</sup>

### ABSTRACT

8 yr old male presented with visual loss, diplopia, ptosis, pain behind the left eye, facial numbness and vomiting of one week duration. The ophthalmological, neurological and radiological examination showed a lesion of the left orbital apex with extension into the cavernous sinus. Examination of the nose and paranasal sinuses did not reveal any abnormality. Transnasal Endoscopic orbital

decompression was performed and inflamed granulation tissue found in the orbital apex was removed. Microbiology showed fungal elements which on culture grew *Aspergillus flavus*. Antifungal therapy with new generation oral drug (voriconazole) resulted in complete resolution of symptoms. Relevant literature is reviewed and discussed.

**Key words:** *Aspergillosis, Orbital Apex Syndrome, Mycoses, Cavernous sinus thrombosis, c + casd*

### INTRODUCTION:

Orbital Apex Syndrome consists of paralysis of all the three nerves (3, 4 & 6) supplying the extra ocular muscles and a sensory deficit in the distribution of the first division of the trigeminal nerve, combined with an optic nerve lesion [1]. Fungal lesions involving the orbital apex are the least common cause of this syndrome. At least 4 forms of fungal infection of the sinonasal tract have been recognized: Allergic, Non-invasive, Invasive and Fulminating. Infection usually spreads from the paranasal sinuses to the orbital Apex. *Aspergillus* is a fungus found in soil and organic debris. It usually presents as a localized disease of the lungs and the paranasal sinuses and mainly affects immunocompromised individuals. But the invasive form can also affect normal or mildly immunocompromised individuals. Orbital *Aspergillosis* is an uncommon condition, and is reported for its rarity and dramatic response to therapy.

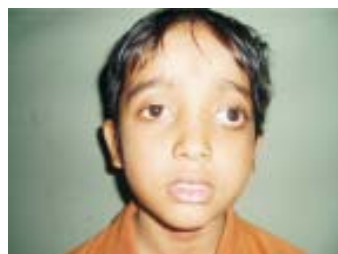### CASE:

An 8 yr old boy presented to the neurosurgery department of Sri Ramachandra Medical College in Nov 2004 with complaints of blurring of vision in left eye following a head injury sustained 2 weeks earlier. He was evaluated and diagnosed to have a left carotico-cavernous fistula for which he underwent embolization with stenting. Patient improved symptomatically with no blurring of vision and was discharged from the hospital.

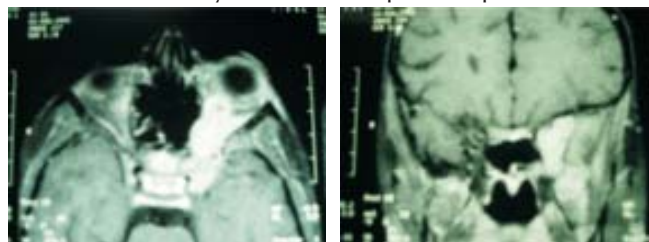
In April 2005, he was readmitted in neurosurgery with history of progressive loss of vision with diplopia of 1 week duration. At that time his vision was restricted to perception of light alone. MRI Brain and Paranasal sinuses revealed an enhancing lesion involving the left orbital apex in T2 weighted images. However all the paranasal sinuses were found to be

normal. In consultation with the ophthalmologist a diagnosis of ? granulomatous lesion was made and the patient treated with corticosteroids and antibiotics for a period of one month. Following this, his vision partially improved and he was discharged from the hospital.

In August, 2005 he was admitted with complaints of progressive worsening of vision in the left eye with diplopia, ptosis, retro-ocular pain, facial numbness and vomiting of 1 week duration. ENT opinion was sought for the same. On clinical examination the patient was conscious and oriented. He had proptosis of left eye and it was pushed outwards and downwards. There was left 3, 4 and 6 cranial nerve palsies with loss of sensation over the left forehead region [Fig. 1].



There was only perception of light in the superior quadrant in the nasal line in the left eye. MRI brain and paranasal sinuses revealed an enhancing lesion in T2 weighted images occupying the left orbital apex with extension to the cavernous sinus [Fig.2,3]. All the paranasal sinuses were however found to be normal and free of disease. The size of the lesion was found to have increased when compared to the earlier scan done in April, 2005. A doppler scan of the left eye revealed superior ophthalmic vein



thrombosis. A diagnostic nasal endoscopy could not be done due to severe pain. All the haematological investigations were within normal limits except ESR which was found to be elevated. Endoscopic biopsy with orbital decompression was done under general anaesthesia and an anterior to posterior approach was used. Uncinectomy with infundibulotomy and middle meatal antrostomy was done on the left side. The

### CORRESPONDING ADDRESS

#### \*Prof. A. RAVIKUMAR

Professor and Head, Dept of ENT,  
Head and Neck Surgery,  
SRMC & RI (DU), Porur, Chennai- 600 116. India.  
email: entsrnc@yahoo.co.in

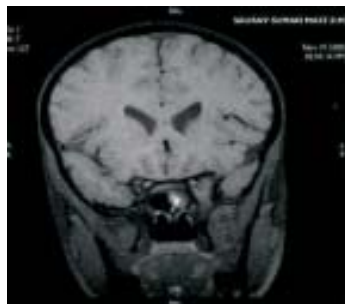anterior and posterior ethmoid air cells were excised, sphenoidotomy was done. A bulge was visualized in the posterior aspect of the lamina papyracea at level of posterior ethmoids. The lamina was opened all the way from the region posterior to the maxillary ostium to the orbital apex. Bulging medial rectus muscle was identified and soft friable tissue was visualized lateral to the medial rectus extending posteriorly. This tissue was removed and sent for histopathological and fungal studies. A complete medial and inferior orbital decompression was done.

The nasal pack was removed on the first post operative day. The proptosis had subsided with partial recovery of the eye movements. The pain had completely subsided, however there was no improvement in vision. The child was on antibiotic coverage in the post operative period. Microbiological studies from biopsy specimen grew *Aspergillus flavus* on Sabouraud's dextrose agar and Lactophenol cotton blue mount revealed septate hyphae with spores and vesicles typical of *Aspergillus flavus* slide culture technique. The patient was started on oral voriconazole (150 mg BD) for a period of three months.

The patient was reviewed at the end of three months. He had full range of eye movements without any ptosis or proptosis [Fig.4]. Visual acuity had improved from perception of light to finger counting at a distance of two feet. Nasal endoscopy showed well



healed mucosa with no evidence of recurrence. A repeat MRI brain and paranasal sinuses showed no evidence of lesion in the region of the left orbital apex. However there was some evidence of disease persisting in the region of the cavernous sinus [Fig.5].



He was advised to continue voriconazole for a further period of 3 months. Patient was reviewed at the end of 6 months and he is totally asymptomatic.

Visual acuity is still confined to finger counting at a distance of two feet. A repeat MRI showed normal contrast uptake in the cavernous sinus and the orbital apex lesion had completely subsided. Patient has been advised to continue voriconazole for a further period of 3 – 6 months.

This case highlights the importance of endoscopic sinus surgery in lesions of the orbital apex.

#### DISCUSSION:

The orbital apex is defined as the region between the posterior ethmoidal foramen and openings of the optic canal and the superior orbital fissure [2]. The apex of the orbit is the entry portal for all the nerves and vessels of the eye and

the site of origin of all extraocular muscles except the inferior oblique. Orbital Apex syndrome can be due to a variety of causes like optic nerve glioma, Intraclinoid aneurysm of the internal carotid artery, trauma, orbital tumors, Paget's disease and fungal infections. Fungal infections are the least common. Only rarely is *Aspergillus* the causative pathology. In humans, almost all the invasive *Aspergillus*; also confirmed by infections are caused by *Aspergillus fumigatus*. In invasive human infections *A.flavus*, *A.glaucus*, *A.niger*, *A.restrictus*, *A.terreus* and *A.versicolor* have been found as causative agents. *Aspergillus fumigatus* is the most common species isolated in human infections, followed by *A.flavus* [3]. Invasive fungal infection is an opportunistic infection. Predisposing causes include alcoholism, low dose prednisolone therapy and diabetes mellitus. The route of infection is frequently by inhalation of *Aspergillus* spores and or airborne metabolites of *aspergillus*, causing at first allergic aspergillosis.

The main routes of central nervous system contamination are hematogenous dissemination from a distant primary source, mainly lung, and contiguous spread from an adjacent focus such as orbit or paranasal sinus [4]. It may manifest as single solid granuloma, multiple abscesses, necrotic lesions or meningitis. CNS aspergillosis is a dramatic disease with a mortality rate of over 90% in immunocompromised patients. Orbital aspergillosis is a rare condition that may mimic non-specific orbital inflammatory disease and hence it goes undiagnosed. Once the infection extends intracranially the morbidity is high in spite of aggressive management.

Systemic aspergillosis is a life threatening opportunistic infection that requires specific antimycotic therapy. Amphotericin B has been the first line drug for systemic therapy in spite of nephrotoxicity. In case of aspergillomata treatment includes aggressive surgical debridement and antifungal therapy with Amphotericin B, Itraconazole or Voriconazole [5]. Voriconazole is a second generation triazole antifungal drug which is very effective against *Aspergillus* species. It has been reported to be superior to Amphotericin B in treatment of *Aspergillus* infections of Paranasal sinuses.

#### REFERENCES:

1. Bray WH, Giangiacomo J, Ide CH. Orbital Apex Syndrome. *Surv Ophthalmol* 1987; 32:136-40.[Medline]
2. Armin Ettl, Karin Zwrtek, Albert Daxer, et al. Anatomy of the Orbital Apex and Cavernous Sinus on High Resolution Magnetic Resonance Images. *Survey of Ophthalmology* 2000; 44:303-23.
3. Swift AC and Denning DW. Skull base osteitis following fungal sinusitis. *J Laryngol Otol* 1998; 112: 92-97 [Medline]
4. Denning DW. Invasive aspergillosis. *Clin Infect Dis* 1998; 26:781-05. [Medline]
5. Massry GG, Hornblass A, Harrison W. Itraconazole in the treatment of orbital aspergillosis. *Ophthalmology* 1996; 103:1467-70.